
Review article

Cervical SNAGs: a biomechanical analysis

A. Hearn,* D. A. Rivett†

**SportsMed, 156 Bealey Avenue, Christchurch, New Zealand;* †*Faculty of Health, The University of Newcastle, University Drive, Callaghan, Newcastle, NSW 2308, Australia*

SUMMARY. A sustained natural apophyseal glide (SNAG) is a mobilization technique commonly used in the treatment of painful movement restrictions of the cervical spine. In the manual therapy literature, the biological basis and empirical efficacy of cervical SNAGs have received scant attention. In particular, an examination of their potential biological basis in order to stimulate informed discussion seems overdue. This paper discusses the likely biomechanical effects of both the accessory and physiological movement components of a unilateral cervical SNAG applied ipsilateral to the side of pain when treating painfully restricted cervical rotation. The use of flexion and extension SNAGs, and rotation SNAGs performed contralateral to the side of pain are not considered. Although a cervical SNAG may clinically be able to resolve painfully restricted cervical spine movement, it is difficult to explain biomechanically why a technique which first distracts (opens) and then compresses (closes) the zygapophyseal joint ipsilateral to the side of pain, and perhaps slightly distracts the uncovertebral cleft, would be superior to a technique which distracts the articular surfaces with both accessory and physiological movement components. Therefore, the reported clinical efficacy of cervical SNAGs cannot be explained purely on the basis of the resultant biomechanical effects in the cervical spine. © 2002 Elsevier Science Ltd. All rights reserved.

INTRODUCTION

The propriety of any therapy can be assessed against three complementary but distinct axes—convention, biological basis, and empirical proof (Bogduk & Mercer 1995). Although a wide range of biological explanations have been proposed for manual therapy (Paterson 1988), it still suffers from a lack of empirically validated treatment procedures (Hurwitz et al. 1996; Koes et al. 1996; Shekelle & Coulter 1997).

A sustained natural apophyseal glide (SNAG) of the cervical spine, first introduced by Mulligan in 1987, is one such procedure. The clinical acceptance (convention) of the cervical SNAG is evinced by the fact that it formed an integral component of approximately 200 continuing education courses in three continents in 1998 (Claassen 1999), in addition to its description in an increasing number of clinical texts (Grieve 1991; Boyling & Palastanga 1994; Petty & Moore 1998).

Cervical SNAGs were the first example of a group of techniques known as mobilizations with movement (MWM) which Mulligan developed to restore pain-free unrestricted movement for most joints in the body (Mulligan 1999). Mulligan (1991, 1994a) proposed that the reputed clinical effectiveness of cervical SNAGs may be biomechanical in nature. However, despite claims of miraculous results using cervical SNAGs (Mulligan 1994b, 1999), an English language search of Medline (1966–September 1999) and CINAHL (1982–September 1999) on-line databases, appropriate texts (Petty & Moore 1998; Mulligan 1999), and cross-referencing of retrieved

Andy Hearn BSc(Cant) DipPhy DMPhty MMPhty(Otago), Manipulative Physiotherapist in Private Practice, SportsMed, 156 Bealey Avenue, Christchurch, New Zealand, **Darren A. Rivett PhD MAppSc(ManipPhy) GradDipManipTher BAppSc(Phy),** Associate Professor, Head, Physiotherapy, The University of Newcastle, Faculty of Medicine and Health Sciences, University Drive, Callaghan, Newcastle, NSW 2308, Australia.

Correspondence to: AH, Manipulative Physiotherapist in Private Practice, SportsMed, 156 Bealey Avenue, Christchurch, New Zealand. Tel.: +64 3 366 0620; Fax: +64 3 366 3514; E-mail: nippercity@yahoo.com

Attributed to: School of Physiotherapy, University of Otago, P.O. Box 56, Dunedin, New Zealand.

literature found no empirical evidence for the efficacy of cervical SNAGs, nor any investigation of the proposed biological basis. The literature on cervical SNAGs is limited, being almost exclusively descriptive and based on clinical experience (Mulligan 1987, 1994a, 1999; Exelby 1995; Rivett et al. 1998). Cervical SNAGs have therefore been chosen as the focus of this review with the expectation that an enhanced understanding of their biomechanical effects may stimulate informed discussion. An initial overview of the application of cervical SNAGs will be followed by an evaluation of the likely biomechanical effects of the technique on articular tissues.

DESCRIPTION OF CERVICAL SNAGS

Method of application

Mulligan (1999) describes a number of specific criteria which constitute a cervical SNAG and which he claims make it distinct from other forms of manual therapy. In particular, a cervical SNAG is applied with the patient seated (Petty & Moore 1998) and thus the spine is in a vertical (i.e. weightbearing or loaded) position. With one thumb (reinforced by the other) placed on the articular pillar of the upper vertebra of the implicated functional-spinal unit (FSU), the therapist applies a sustained passive accessory intervertebral movement (PAIVM) superoanteriorly along the facet plane. This 'glide' is maintained as the patient moves actively through the desired range of physiological movement and then whilst sustaining the end-range position for a few seconds. Over-pressure can also be added by the patient to the physiological movement. The 'glide' is released by the therapist after the patient returns to the starting position for the active movement. The cardinal rule governing this procedure is that all movement, both accessory and physiological, must be painless (Mulligan 1994a, 1999).

The point of application for the glide can be either unilateral (on the articular pillar) or central (on the spinous process). Unilateral application of the accessory movement is recommended by Mulligan (1999), as he suggests spinal lesions are generally unilateral. The subsequent active physiological movement is nearly always in the direction of a painful movement loss (Mulligan 1994a). Thus, a patient with painfully restricted right rotation would initially be treated with a unilateral SNAG on the ipsilateral (right) articular pillar (Mulligan 1999) (Fig. 1). If this did not immediately improve the patient's active range, a SNAG would next be applied to the superior facet of the zygapophyseal joint on the left, or failing that, centrally (i.e. bilaterally) via the superior spinous process of the implicated segment (Mulligan 1999). The accessory glide is always applied in a

superoanterior direction parallel to the facet plane, irrespective of whether the patient's dysfunction predominantly involves flexion, extension, rotation or lateral flexion.

Previously proposed biological basis

It has been suggested that MWMs (including cervical SNAGs) may correct '...minor bony positional faults, not palpable or visible on X-ray...' (Mulligan 1993, p 155), or that they correct (static) 'positional faults' and (dynamic) 'mal-tracking' problems (Mulligan 1992; Wilson 1995; Petty & Moore 1998). Specifically, cervical SNAGs are said to cause a repositioning of the articular facet allowing normal pain-free function (Mulligan 1994a) and as such are thought to primarily mobilize the zygapophyseal joint, while still obviously influencing the entire FSU, including the intervertebral disc (IVD) (Mulligan 1994a). This approach is extrapolated from Kaltenborn's theory (1989) that decreased joint gliding of the peripheral joints can contribute significantly to joint hypomobility and therefore to impaired joint function (Mulligan 1999). Excluding reiteration of these ideas by others (Wilson 1994; Exelby 1995; Petty & Moore 1998), the literature on cervical SNAGs remains bereft of a biological basis.

Given the clinical popularity and unsubstantiated efficacy of cervical SNAGs, discussion of their biological basis seems warranted. The following review will primarily focus on the relevant biomechanics of the articulations of the FSU (the zygapophyseal and interbody joints) as they relate to the potential mechanism(s) of action of cervical SNAGs. Only the articulations of cervical spine segments C2-3 to C6-7 will be considered as they represent a relatively homogenous group anatomically and biomechanically (Taylor & Twomey 1994). It is acknowledged that other spinal structures, such as certain neural tissues or surrounding musculature, may play a role in the mechanism of action of cervical SNAGs, but are not considered for the purposes of this review.

BIOMECHANICAL ANALYSIS OF CERVICAL SNAGS

Accessory joint glide

Cervical SNAGs are purported to produce an accessory 'glide' (Maitland 1986) of the superior facet parallel to the articular surfaces of a fully loaded cervical zygapophyseal joint (Mulligan 1999). Implicit in this description is the assumption that the therapist can produce movement of one joint surface relative to the other. Some limited evidence exists to support this presumption (Thompson 1983; Lee &

Evans 1991, 1992; Nathan & Keller 1994; Gal et al. 1997), although it is important to note that these studies (using mobilization and manipulation procedures) have all been conducted on lumbar and thoracic spine segments in prone-lying (unloaded), therefore limiting the applicability of their findings to cervical SNAGs.

Thompson (1983) simulated a PAIVM by applying a 250 N posteroanterior (PA) force to the L3 spinous process and demonstrated that the caudal joint (L3–4) exhibited more relative displacement (3–5 mm) than the cephalad (L2–3) joint (1–3 mm). Lee and Evans (1991), using a biomechanical model, also predicted relative intervertebral movements when a PA force of 150 N was applied to the spinous process of L4. In their analysis, they assumed that there were no significant horizontal compressive forces through the spine and only loadings in the sagittal plane were considered. However, it is possible that the unilateral application of a cervical SNAG will produce axial (y -axis), lateral (z -axis) and sagittal (x -axis) rotations, as demonstrated during unilateral thoracic manipulation (Gal et al. 1997).

There are several findings from these studies that are relevant to the present discussion. Firstly, Lee & Evans (1992) demonstrated that absolute PA displacement was rate dependant, as it was inversely proportional to the rate of force application due to the viscoelastic properties of human tissue. Therefore, cervical SNAGs could theoretically produce greater accessory gliding movement than a similar, faster procedure such as a manipulation (high-velocity thrust technique). Secondly, the model by Lee & Evans (1991) predicted that motion segments above the level of mobilization are subjected to posterior shear forces, and segments below to substantially larger anterior shear forces. Although facet angles differ considerably between the lumbar and cervical spines, this finding may be relevant to the cervical spine as the superior facet of the FSU sits posteriorly in relation to its inferior partner (as it does in the lumbar spine) and therefore the caudal joint of a vertebra being mobilized may experience a larger (anterior) shear force, in accordance with the results of Thompson (1983). This is consistent with the segment targeted by cervical SNAGs, namely the FSU inferior to the vertebra being mobilized. Thirdly, although Lee & Evans (1992) demonstrated the phenomenon of 'creep' (with 69% of creep occurring within the first 30 s), connective tissue creep of tissues ipsilateral to the side of pain and unilateral SNAG application is unlikely to play a significant role in the biomechanical effects of a SNAG. In particular, the considerable zygapophyseal joint capsular laxity demonstrated by Onan (1998) would mitigate against significant creep of the implicated capsule. Finally, Lee & Evans (1991,

1994) predicted a complex motion pattern involving both extension-rotation (x -axis) and translatory movement (z -axis) during posteroanteriorly directed mobilization of the lumbar spine. If the cervical spine responds in a manner similar to the superoanteriorly directed glide during a cervical SNAG, a similarly complex spinal motion pattern may occur, potentially increasing the cervical lordosis and therefore weight-bearing through the posterior columns. These effects will now be considered.

THE EFFECTS OF SPINAL LOADING

Pal & Sherk (1988) demonstrated that at the level of the sixth cervical vertebra in the neutral position, 36% of the total load is transmitted through the anterior column and 32% through each of the two posterior columns. This compressive force is likely to increase stiffness or 'resistance' (Maitland 1986; Jull et al. 1988) to accessory movement and therefore decrease the amount of accessory glide achieved with a given force in the sitting position (relative to prone-lying). Mulligan (1999) does not, however, attempt to quantify the required manual gliding force, a situation common to most, if not all, manual therapy procedures (Bjornsdottir & Kumar 1997).

Further compounding the effect of gravitational spinal loading is the compressive effect of muscle function (Lee et al. 1993; Shirley et al. 1999) and of an increased cervical lordosis (Lee & Evans 1994). Following the application of an accessory glide, the patient will attempt to maintain the head in a position of equilibrium, probably by recruiting the cervical extensor musculature and by increasing the cervical lordosis. The biomechanical effects of the spinal musculature have been demonstrated in the lumbar spine where voluntary extensor muscle activity significantly increased lumbar stiffness to PA movement/forces in prone-lying (Lee et al. 1993; Shirley et al. 1999). These factors suggest that compressive forces, whether they are due to muscle spasm, voluntary stabilizing muscular activity, or to gravity in an upright position, are likely to increase stiffness and therefore reduce accessory movement for a given gliding force.

In summary, it is probable that accessory joint motion, however small, may be produced in an unloaded cervical FSU, but the effects of an erect posture are likely to make this more difficult to achieve. It is also probable that with cervical SNAGs quite large forces would be required to produce relatively small joint displacements (Matyas & Bach 1985; Lee & Evans 1994), and the compressive forces resulting from the patient's efforts to first maintain equilibrium and then move actively may rise proportionally with an increasing manual gliding force.

Active physiological movement

The kinematics of the mid-lower cervical spine appear reasonably well established (Lysell 1969; White & Panjabi 1990), while cervical kinetics are not well understood (Mercer 1996; Kamibayashi & Richmond 1998; Bernhardt et al. 1999). Therefore, an analysis of the active movement component of a cervical SNAG will primarily involve a kinematic assessment of the chosen technique. For the purposes of this discussion a unilateral SNAG, performed ipsilateral to the side of pain and movement restriction for an adult patient with painfully restricted right rotation, will be used as an example (Fig. 1).

As the patient commences turning to the right, the accessory glide having been applied and maintained, two important events occur. Firstly, muscle activity is initiated to produce movement; and secondly, obligatory coupled motion (White & Panjabi 1990) of the cervical FSU occurs about a constantly shifting axis (Milne 1993; Penning 1998).

Muscle function

To be maximally effective at a given task, the line of action of a muscle must be tangential with respect to

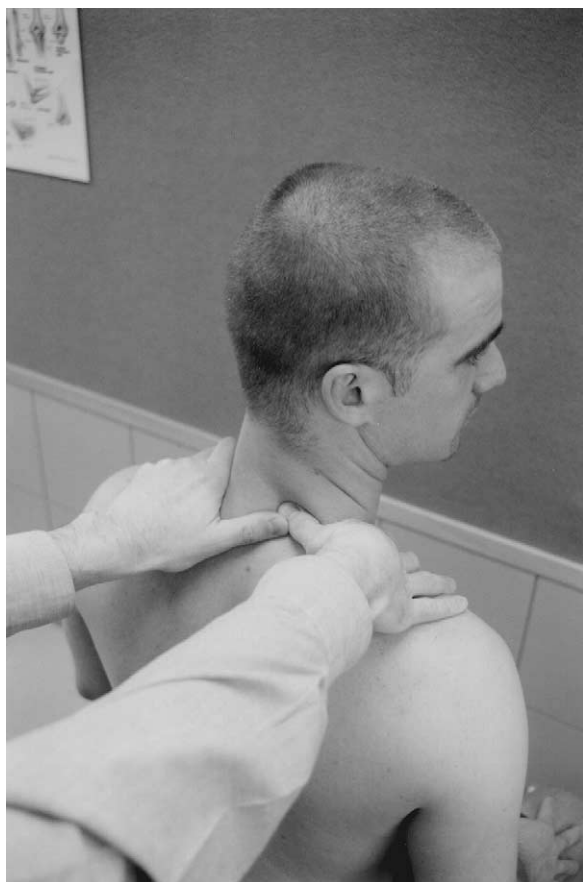

Fig. 1—Application of a unilateral cervical SNAG, administered to C5 on the right articular pillar, for a patient with painfully restricted right rotation at the C5–6 motion segment.

the centre of motion (Penning 1998). However, during cervical axial rotation, the relatively vertical orientation of cervical musculature (Kamibayashi & Richmond 1998) is likely to result in greater compressive than horizontal rotatory forces. As the neck rotates to the right, muscle contractile activity will produce a compressive force, particularly through the right articular pillar. In combination, these forces may oppose or perhaps even reverse the already small, manually applied glide component of the cervical SNAG by drawing the superior facet of the FSU posteroinferiorly along the plane of the articular facet. While there are no data to suggest the resultant joint displacement between the therapist applied superoanterior glide and the opposing forces of muscular contraction and gravity, a review of mid-lower cervical spine kinematics will facilitate a discussion of the possible articular effects of the chosen technique.

Coupled motion about an axis

The mid-lower cervical spine has been shown to undergo obligatory ipsilateral coupling of rotation and lateral flexion (Lysell 1969) about an oblique axis of motion (Penning 1989; Milne 1993). This may be largely due to the geometry of the cervical articular facets and the orientation of the uncinat processes (Lysell 1969; Penning 1989; White & Panjabi 1990; Mercer 1996). Lysell (1969) demonstrated that between C2 and C7 there is a gradual cephalocaudal decrease in the amount of lateral flexion that is associated with axial rotation, possibly due to a gradual cephalocaudal decrease in the angle of inclination of the facet joints to the frontal plane. On average, however, the mid-lower cervical articular facets are said to lie at approximately 45° to the frontal plane (Milne 1993; Taylor & Twomey 1994).

In addition to its slight upward convexity in the sagittal plane, the uncinat processes have given the cervical vertebral body a marked upward concavity in the frontal plane, thus providing a saddle shape that has two axes of motion perpendicular to each other and located on opposite sides of the joint (Milne 1993; Penning 1998). Milne (1993) computed the parameters of the finite helical axis for composite mid-lower cervical spine motion. This axis completely describes FSU composite motion as a rotation about, and a translation along, a helical axis with a known position and orientation in space. The position and inclination of the helical axis, which passes obliquely upwards and backwards through the moving vertebral body (Milne 1993) (Fig. 2), suggests that the anterior part of each cervical disc acts like a pivot (Penning 1998; Mercer & Bogduk 1999). The posterior part of the disc, with its uncovertebral cleft flanked by uncinat processes, therefore acts like a socket within which the superior vertebral body of the FSU rolls (Penning 1989; Milne 1993; Mercer

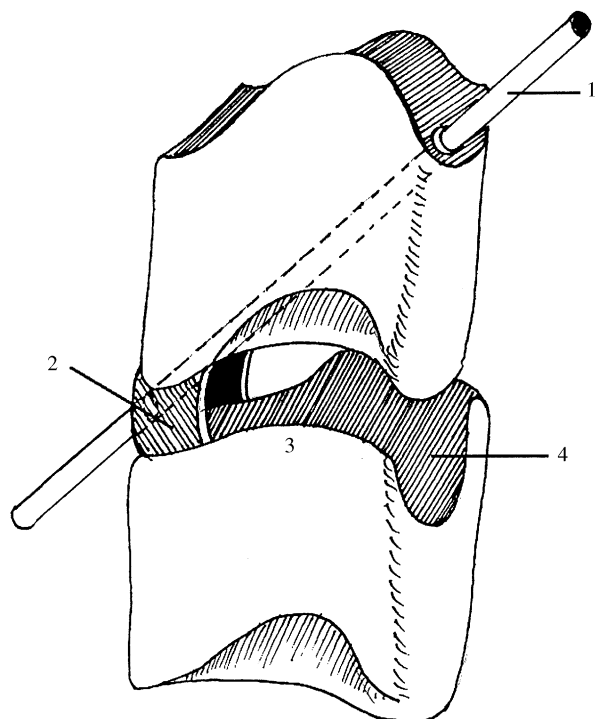


Fig. 2—The axis of coupled motion: (1) in the mid-to-lower cervical spine passes through the anterior cervical disc; (2) which acts as a pivot point, while the uncinate processes; (3) help form the saddle shaped joint; (4) which acts as a socket.

1996). The uncinate processes and the uncovertebral clefts in the IVD may thus act as the joint surfaces for these saddle joints of the mid-lower cervical spine (Penning 1989; Milne 1993; Bogduk 1994; Mercer 1996).

It has therefore been suggested that mid-lower cervical spine 'coupled' motion be viewed from the plane of the facet joint (Penning 1989), which is consistent with Milne's (1993) finding that the axis of composite motion is more or less perpendicular to the plane of the facet joint. It is also consistent with application of the glide component of a cervical SNAG in a superoanterior direction. In the mid-lower cervical spine, lateral flexion and axial rotation are therefore interpreted as the same movement (Penning 1989; Milne 1993). This may somewhat explain the clinical finding with cervical SNAGs that the same superoanterior accessory joint movement is needed, whether the movement dysfunction involves rotation or lateral flexion (Mulligan 1999). The helical axis of composite motion (Milne 1993) suggests that for rotatory cervical movement the axis of motion lies close to the ipsilateral zygapophyseal joint. This implies that when applying an ipsilateral cervical SNAG to treat painfully restricted right rotation, the contralateral (left) superior articular surface is sliding upward and forward in a flexion-like fashion (Worth 1994), while its ipsilateral (right) equivalent may be limited in its posteroinferior movement by the manually applied superoanterior

force. This point is of considerable importance when assessing the potential effects of cervical SNAGs on articular structures.

It therefore seems likely that the 'glide' component of a cervical SNAG would create an artificial axis of motion by altering (or blocking) movement of the ipsilateral zygapophyseal joint. The therapist's thumbs would become a fulcrum for rotatory movement about which the interbody and contralateral zygapophyseal joints would move, therefore emphasizing the ipsilateral location of the axis of composite motion for this movement (Milne 1993) (Fig. 3). This

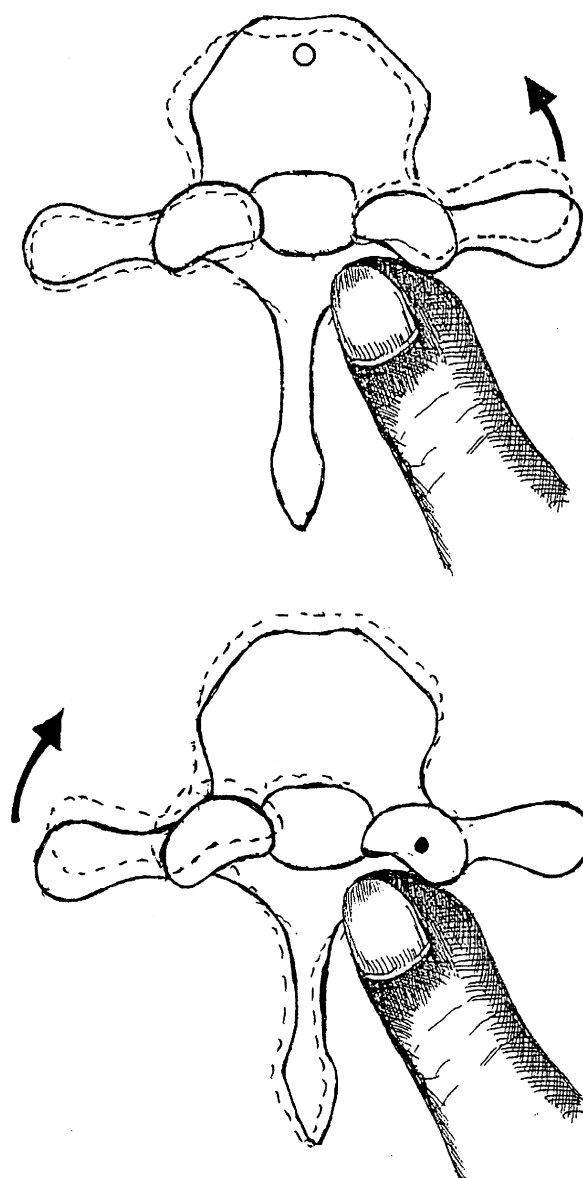


Fig. 3—Superior view of the two phases of segmental movement which occur during the application of a unilateral cervical SNAG to the right articular pillar. Top: manual force is applied in an attempt to achieve superoanterior accessory movement at the right zygapophyseal joint. The normal axis of coupled motion can be seen (open circle). Bottom: the manually applied force creates a new axis of motion (closed circle) about which active rotation to the right occurs, 'opening up' the left zygapophyseal joint.

could result in a segmental decrease in coupled motion at the ipsilateral zygapophyseal joint but possibly an increase in the arc of movement, specifically superoanterior glide (flexion) of the contralateral zygapophyseal joint (due to it being further from the axis of movement). The primary mechanical effects of this altered motion are likely to be reduced posteroinferior glide (closing down) of the ipsilateral superior facet, increased superoanterior glide (opening up) of the contralateral superior facet, and the relative distraction or unloading of the uncovertebral cleft as a result of the altered facet motion.

DISCUSSION

Due to an almost complete lack of empirical evidence supporting the clinical use of cervical SNAGs, a discussion of the potential effects of the technique on the FSU biomechanics and the articular tissues of the mid-lower cervical spine is worthwhile. However, several assumptions related to the clinical application of cervical SNAGs require stating beforehand. Firstly, given that cervical SNAGs are said to have an immediate effect (Mulligan 1999), it seems likely that their underlying mechanism is either purely mechanical, reflexogenic (Herzog et al. 1999), or a combination of the two, and does not primarily involve chemical processes or natural resolution (Wall 1992). Secondly, Mulligan (1999) states that cervical SNAGs are specific in their effects to a single FSU, potentially excluding mechanisms such as the placebo effect (Wall 1992), the 'laying on of hands' (Zusman 1986), and therapist charisma (Hartman 1985). Thirdly, it is unlikely that osseous pathology would undergo immediate and prolonged improvement following mobilization, thus implicating soft tissue structures such as meniscoid inclusions, the zygapophyseal joint capsule and intervertebral disc as the most likely articular sources for any manually reversible pain.

The role of meniscoid inclusions in zygapophyseal joint dysfunction has been proposed to include either 'entrapment' of the meniscoid between articular surfaces or possibly 'extrapment' by its deflection on the articular margin when returning to the neutral position from an opened/flexed position (Bogduk & Jull 1984; Giles 1986; Mercer & Bogduk 1993; Mercer 1994) (Fig. 4). Either mechanism could be a primary or secondary (through tractioning of the zygapophyseal joint capsule) source of pain and muscle spasm (Saboe 1988; Mercer 1994). Meniscoids may also act as a nidus for fibrous tissue proliferation eventually leading to adhesion formation (Mercer 1994). Potentially, the accessory glide component of a cervical SNAG could ameliorate any of these problems by either separating the facet surfaces and releasing the

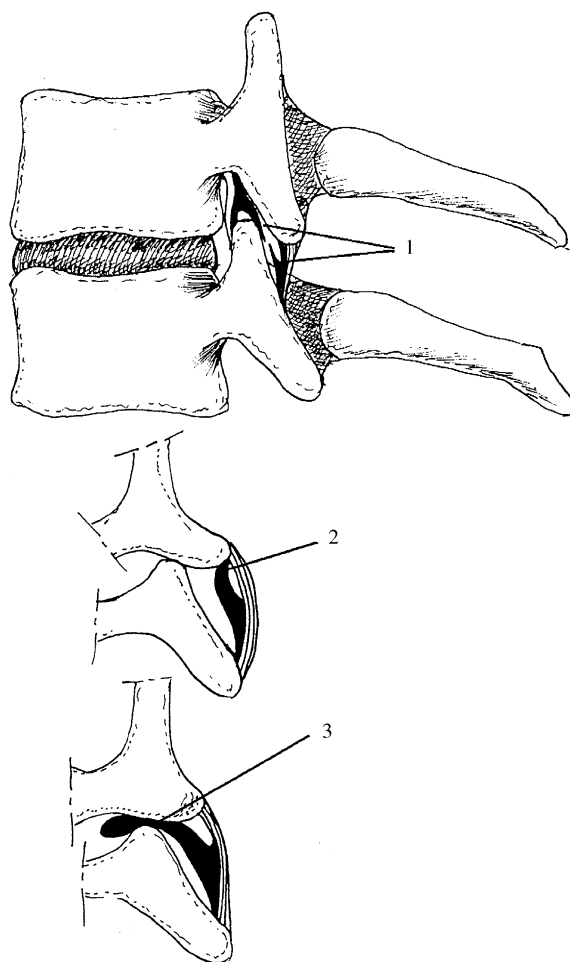


Fig. 4—Possible involvement of meniscoid inclusions in zygapophyseal joint movement dysfunction. Top: meniscoids (1) sitting normally between the articular surfaces. Middle: an example of meniscal extrapment with the meniscoid becoming trapped outside the articular surfaces (2). Bottom: an example of meniscal entrapment with the meniscoid becoming pinched between the articular surfaces (3).

entrapped meniscoid, or by allowing the extrapped meniscoid to return to its intra-articular position, or perhaps by stretching adhesions.

What is difficult to explain is why the accessory glide should be performed in a weightbearing or loaded position given the likely associated limitation of accessory motion. Further complicating matters is the effect of ipsilateral active movement, which is also likely to reduce the accessory glide and cause increased zygapophyseal joint compression. On the basis of the previous biomechanical analysis it would seem more appropriate to apply the accessory glide ipsilateral to the side of pain before performing physiological movement away from the side of pain (contralateral), as this would cause less joint compression, greater excursion of movement at the symptomatic FSU, and presumably a greater chance of stretching adhesions and resolving any meniscal entrapment or extrapment. This approach would be

similar to that advocated for the treatment of locked cervical joints, which involves maximal opening or distraction of the 'locked' zygapophyseal joint (Maitland 1978; Sprague 1983).

The cervical disc has been implicated as a primary source of cervical spine dysfunction (Cyriax 1978; McKenzie 1990), but often on the basis of questionable anatomical models (Mercer & Jull 1996). Nevertheless, current knowledge suggests that the IVD is a potential source of pain. Notably, the uncovertebral cleft, a normal adaptive pseudo-articulation (Taylor & Twomey 1994; Mercer & Bogduk 1999), could conceivably be innervated and is intimately associated with the richly innervated posterior longitudinal ligament (Groen et al. 1990; Mercer & Bogduk 1999). In the lower cervical spine, disc fissuring may start at the centre of the disc and radiate in all directions, eventually becoming confluent and forming sequestra (Tondury 1958; Ecklin 1960). Fully or partially detached IVD fragments could constitute a painful impediment to the gliding motion at the uncovertebral cleft, with the direction and degree of restriction possibly depending on the size and orientation of the IVD fragment. Alternatively, the alar fibres of the deep layer of the posterior longitudinal ligament and the associated periosteofascial tissue (Mercer & Bogduk 1999) may be vulnerable to impingement within the uncovertebral cleft as it 'closes down' ipsilateral to the side of active movement. In either case, the accessory glide component of a cervical SNAG could potentially facilitate painfree motion by distracting the ipsilateral portion of the uncovertebral cleft. However, the previous biomechanical analysis does not indicate as to why any improvement would be further enhanced by ipsilateral active movement.

Mulligan (1994a) has put forward a theory which could help to explain the need for ipsilateral physiological rotation during application of a cervical SNAG. He suggests that the superior facet of the implicated FSU ipsilateral to the side of pain may be jammed posteroinferiorly in an extension or 'closed down' position; hence, ipsilateral rotation could cause pain due to excessive 'closing down' of the zygapophyseal joint. Application of the accessory glide component of a cervical SNAG may therefore reposition the superior facet superoanteriorly allowing a greater range of painfree ipsilateral rotation. Other approaches to manual therapy also consider spinal joint malalignment and subluxation as potentially reversible causes of spinal pain (Triano 1992; Katavich 1998), however, there remains a disparity between symptomatology and radiographic findings (Gore et al. 1986; Johnson & Lucas 1997). It is arguable that a subluxation or minor positional fault of a joint is no more common in persons with spinal pain than those without (Grieve 1981; Yi-Kai et al. 1998) and it is difficult to explain both as to why a

minor subluxation or positional fault would occur, and why it would remain 'corrected' after several repetitions of a cervical SNAG.

CONCLUSION

The cervical SNAG is a popular manual therapy technique used widely in the treatment of painful and restricted neck movement. Its clinical application has been based almost exclusively on convention with little attempt to provide a biological basis and little, if any, empirical evidence as yet to support its efficacy. To this end, the present review has attempted to analyse the possible biomechanical effects of a SNAG applied to the articular pillar of the cervical spine. Several potentially reversible sources of articular pain and impaired function, mainly involving impingement of innervated tissue between either zygapophyseal joint or IVD articular surfaces, have been considered. Although the chosen technique could theoretically resolve these problems it is difficult to explain biomechanically why a technique which first distracts and then compresses the ipsilateral zygapophyseal joint, and perhaps slightly distracts the ipsilateral aspect of the uncovertebral cleft, would be superior to a technique which distracts the articular surfaces with both accessory and physiological movement components. This latter scenario could be effected by applying an ipsilateral accessory glide followed by contralateral active rotation. It is interesting to note, however, that Mulligan's (1999) second choice technique in this case would be to apply the accessory glide contralateral to the side of pain but still perform active movement ipsilateral to the painful side, in effect, compressing the FSU ipsilateral to the side of pain with both accessory and physiological movement components. Other than it being the functionally impaired movement, the necessity for active movement towards the side of pain is difficult to explain on the basis of biomechanics alone. There remains a need for clinical trials of cervical SNAGs, perhaps including the aforementioned alternate combinations of accessory and physiological movement, in order to provide empirical evidence to support their reported clinical efficacy.

Acknowledgements

We would like to thank Associate Professor Peter Milburn and Jean Hay-Smith, School of Physiotherapy, and also Dr Susan Mercer, Department of Anatomy and Structural Biology, University of Otago, for their helpful comments.

References

- Bernhardt P, Wilke H, Wenger K, Jungkunz B, Bohm A, Claes L 1999 Multiple muscle force simulation in axial rotation of the cervical spine. *Clinical Biomechanics* 14: 32-40

- Bjornsdottir S, Kumar S 1997 Posteroanterior spinal mobilization: a state of the art review and discussion. *Disability and Rehabilitation* 19: 39–46
- Bogduk N 1994 Biomechanics of the cervical spine. In: Grant R (ed.) *Physical Therapy of the Cervical and Thoracic Spine*, 2nd edn. Churchill Livingstone, London, pp 27–46
- Bogduk N, Jull G 1984 The theoretical pathology of acute locked back: a basis for manipulative therapy. *Manual Medicine* 1: 1–5
- Bogduk N, Mercer S 1995 Selection and application of treatment. In: Refshauge K, Gass E (eds) *Musculoskeletal Physiotherapy: Clinical Science and Practice*. Butterworth Heinemann, London, pp 169–181
- Boyling J, Palastanga N (eds) 1994 *Grieve's Modern Manual Therapy: The Vertebral Column*, 2nd edn. Churchill Livingstone, Edinburgh
- Claassen R 1999 Survey of Mulligan Concept Teachers' Association members. Mulligan Concept Teachers' Association, Vught, Netherlands
- Cyriax J 1978 *Textbook of Orthopaedic Medicine, Vol I: Diagnosis of Soft Tissue Lesions*, 7th edn. Bailliere Tindall, London
- Ecklin U 1960 *Die Altersveränderungen der Halswirbelsäule*. Springer, Berlin (cited in Penning, 1998)
- Exelby L 1995 Mobilization with movement: a personal view. *Physiotherapy* 12: 724–729
- Gal J, Herzog W, Kawchuk G, Conway D, Zhang Y-T 1997 Movements of vertebrae during manipulative thrusts to unembalmed human cadavers. *Journal of Manipulative and Physiological Therapeutics* 20: 30–40
- Giles L 1986 Lumbo-sacral and cervical zygapophyseal joint inclusions. *Manual Medicine* 2: 89–92
- Gore D, Sepic S, Gardner G 1986 Roentgenographic findings of the cervical spine in asymptomatic people. *Spine* 11: 521–524
- Grieve G 1981 *Common Vertebral Joint Problems*. Churchill Livingstone, Edinburgh
- Grieve G 1991 *Mobilization of the Spine*, 5th edn. Churchill Livingstone, Edinburgh
- Groen G, Baljet B, Drukker J 1990 Nerves and nerve plexuses of the human vertebral column. *The American Journal of Anatomy* 188: 282–296
- Hartman L 1985 Classification and application of osteopathic manipulative techniques. In: Glasgow E, Twomey E, Scull L, Kleynhams E, Idczak A (eds) *Aspects of Manipulative Therapy*. Churchill Livingstone, London, pp 81–86
- Herzog W, Scheele D, Conway P 1999 Electromyographic responses of back and limb muscles associated with spinal manipulative therapy. *Spine* 24: 146–153
- Hurwitz E, Aker P, Adams A, Meeker W, Shakelle P 1996 Manipulation and mobilization of the cervical spine: a systematic review of the literature. *Spine* 21: 1746–1760
- Johnson M, Lucas G 1997 Value of cervical spine radiographs as a screening tool. *Clinical Orthopaedics and Related Research* 340: 102–108
- Jull G, Bogduk N, Marsland A 1988 The accuracy of manual diagnosis for cervical zygapophyseal joint pain syndromes. *Medical Journal of Australia* 148: 233–236
- Kaltenborn F, Evjenth O 1989 *Manual Mobilization of the Extremity Joints*, 4th edn. Olaf Norlis Bokhandel, Oslo
- Kamibayashi L, Richmond J 1998 Morphometry of human neck muscles. *Spine* 23: 1314–1323
- Katavich L 1998 Differential effects of spinal manipulative therapy on acute and chronic muscle spasm: a proposal for mechanisms and efficacy. *Manual Therapy* 3: 132–139
- Koes B, Assendelft W, van der Heijden G, Bouter L 1996 Spinal manipulation for low back pain: an updated systematic review of randomised clinical trials. *Spine* 21: 2860–2873
- Lee M, Esler M-A, Mildren J, Herbert R 1993 Effect of extensor muscle activation on the response to lumbar posteroanterior forces. *Clinical Biomechanics* 8: 115–119
- Lee R, Evans J 1991 Biomechanics of spinal posteroanterior mobilisation. Proceedings of the 7th Biennial Conference of the Manipulative Physiotherapists' Association of Australia, Blue Mountains, New South Wales, pp 59–64
- Lee R, Evans J 1992 Load–displacement–time characteristics of the spine under posteroanterior mobilization. *The Australian Journal of Physiotherapy* 38: 115–123
- Lee R, Evans J 1994 Towards a better understanding of spinal posteroanterior mobilization. *Physiotherapy* 80: 68–73
- Lysell E 1969 Motion in the cervical spine. *Acta Orthopaedica Scandinavica Supp.* 123
- Maitland G 1978 Acute locking of the cervical spine. *The Australian Journal of Physiotherapy* 24: 103–109
- Maitland G 1986 *Vertebral Manipulation*, 5th edn. Butterworth Heinemann, London
- Matyas T, Bach T 1985 The reliability of selected techniques in clinical arthrometrics. *The Australian Journal of Physiotherapy* 31: 175–199
- McKenzie R 1990 *The Cervical and Thoracic Spine: Mechanical Diagnosis and Therapy*. Spinal Publications (NZ) Ltd, Waikanae
- Mercer S 1994 The menisci of the cervical synovial joints. In: Boyling J, Palastanga N (eds) *Grieve's Modern Manual Therapy: The Vertebral Column*, 2nd edn. Churchill Livingstone, Edinburgh, pp 69–72
- Mercer S 1996 *Orthopaedic Physical Therapy Home Study Course 96-1: Biomechanics of the Cervical Spine*. University of Pittsburgh, Medical Center, Pittsburgh, USA
- Mercer S, Bogduk N 1993 Intra-articular inclusions of the cervical synovial joints. *British Journal of Rheumatology* 32: 705–710
- Mercer S, Bogduk N 1999 The ligaments and anulus fibrosus of human adult cervical intervertebral discs. *Spine* 24: 619–628
- Mercer S, Jull G 1996 Morphology of the cervical intervertebral disc: implications for McKenzie's model of the disc derangement syndrome. *Manual Therapy* 2: 76–81
- Milne N 1993 Composite motion in cervical disc segments. *Clinical Biomechanics* 8: 193–202
- Mulligan B 1987 Sustained NAGS (SNAGS) in the treatment of the cervical spine. *The New Zealand Journal of Physiotherapy* 15: 12
- Mulligan B 1991 Vertigo...Manual therapy may be needed. Proceedings of the 7th Biennial Conference of the Manipulative Physiotherapists' Association of Australia, Blue Mountains, New South Wales, pp 46–47
- Mulligan B 1992 Extremity joint mobilisations combined with movements. *The New Zealand Journal of Physiotherapy* 20: 28–29
- Mulligan B 1993 Mobilisations with movements. *The Journal of Manual and Manipulative Therapy* 1: 154–156
- Mulligan B 1994a 'SNAGS': mobilisations of the spine with active movement. In: Boyling J, Palastanga N (eds) *Grieve's Modern Manual Therapy: The Vertebral Column*, 2nd edn. Churchill Livingstone, Edinburgh, pp 733–743
- Mulligan B 1994b Spinal mobilisations with arm movements (further mobilisations with movement). *The Journal of Manual and Manipulative Therapy* 2: 75–77
- Mulligan B 1999 *Manual Therapy, "NAGS", "SNAGS", "MWM'S", etc*, 4th edn. Plane View Services, Wellington
- Nathan M, Keller T 1994 Measurement and analysis of the in-vivo posteroanterior impulse response of the human thoracolumbar spine: a feasibility study. *Journal of Manipulative and Physiological Therapeutics* 17: 431–441
- Onan O, Heggeness M, Hipp J 1998 A motion analysis of the cervical facet joint. *Spine* 23: 430–439
- Pal G, Sherk H 1988 The vertical stability of the cervical spine. *Spine* 13: 447–449
- Paterson J 1988 Spinal manipulation: Science or black art? *The Practitioner* 232: 289–291
- Penning L 1989 Physiology and biomechanics: functional anatomy of joints and discs. In: Clark C (ed) *The Cervical Spine*, 2nd edn. J B Lippincott Company, London, pp 33–56
- Penning L 1998 Normal kinematics of the cervical spine. In: Giles L, Singer K (eds) *Clinical Anatomy and Management of Cervical Spine Pain*. Butterworth Heinemann, London, pp 53–70
- Petty N, Moore A 1998 *Neuromusculoskeletal Examination and Assessment: a Handbook for Therapists*. Churchill Livingstone, London
- Rivett D, Milburn P, Chapple C 1998 Negative pre-manipulative vertebral artery testing despite complete occlusion: a case of false negativity? *Manual Therapy* 3: 102–107
- Saboe L 1988 Possible clinical significance of intra-articular synovial protrusions: a review of the literature. *Manual Medicine* 3: 148–151
- Shekelle P, Coulter I 1997 Cervical spine manipulation: summary report of a systematic review of the literature and a

- multidisciplinary expert panel. *Journal of Spinal Disorders* 10: 223–228
- Shirley D, Lee M, Ellis E 1999 The relationship between submaximal activity of the lumbar extensor muscles and lumbar posteroanterior stiffness. *Physical Therapy* 79: 278–285
- Sprague R 1983 The acute cervical joint lock. *Physical Therapy* 63: 1439–1444
- Taylor J, Twomey L 1994 Functional and applied anatomy of the cervical spine. In: Grant R (ed) *Physical Therapy of the Cervical and Thoracic Spine*, 2nd edn. Churchill Livingstone, London, pp 1–26
- Thompson R 1983 Measurement of relative intervertebral displacement in the lumbar spine during application of a PAIVM. Unpublished Postgraduate Diploma Dissertation, Lincoln Institute of Health Sciences, Melbourne (cited in Matyas and Bach 1985)
- Tondury G 1958 *Entwicklungsgeschichte und Fehlbildungen der Wirbelsäule*. Hippokrates, Stuttgart (cited in Penning 1998)
- Triano J 1992 Studies on the biomechanical effect of a spinal adjustment. *Journal of Manipulative and Physiological Therapeutics* 15: 71–75
- Wall P 1992 The placebo effect: an unpopular topic. *Pain* 51: 1–3
- White A, Panjabi M 1990 *Clinical Biomechanics of the Spine*, 2nd edn. J B Lippincott, Philadelphia
- Wilson E 1994 Mobilisation with movement: an update. In *Touch* 73: 10–11
- Wilson E 1995 Mobilisation with movement and adverse neural tension: an exploration of possible links. *Manipulative Physiotherapist* 27: 40–46
- Worth D 1994 Movements of the head and neck. In: Boyling J, Palastanga N (eds) *Grieve's Modern Manual Therapy: The Vertebral Column*, 2nd edn. Churchill Livingstone, Edinburgh, pp 53–68
- Yi-Kai L, Yun-Kun Z, Shi-Zhen Z 1998 Diagnostic value on signs of subluxation of cervical vertebrae with radiological examination. *Journal of Manipulative and Physiological Therapeutics* 21: 617–620
- Zusman M 1986 Spinal manipulative therapy: review of some proposed mechanisms and a new hypothesis. *The Australian Journal of Physiotherapy* 32: 89–99